

Clinical Case Report

Endodontic treatment of a mandibular first molar with six root canals – A case report



André Luiz da Costa Michelotto¹ , Lisa Yurie Oda^{1,*} , Antonio Batista¹ 

¹ Federal University of Paraná, Curitiba, Paraná, Brazil.

ARTICLE INFO

Article history:

Received 8 December 2022

Accepted 21 June 2023

Available online 30 June 2023

Keywords:

Anatomic variation

Endodontics

Molar

Root canal preparation

Root canal therapy

ABSTRACT

The mandibular first molar usually has a mesial root with two root canals and a distal root with one or two root canals. However, variations in this morphology, such as multiple root canals, may occur. A 20-year-old male patient presented with a chief complaint of pain and swelling in the left mandibular region. Based on clinical and radiographic exams, the diagnosis of symptomatic apical periodontitis was established. Initially, two root canals in the mesial root and two in the distal root of tooth #36 were located and negotiated using a dental operating microscope. After further exploration, two more root canals were located in the mesial root. The six root canals were prepared. For the final rinse, the irrigant solutions were agitated with an ultrasonic tip. Calcium hydroxide dressing was used, and one month later, the patient presented without signs or symptoms. The root canal filling was performed using the single-cone technique with gutta-percha cones and bioceramic endodontic sealer. At the 12-month follow-up, a periapical radiograph showed bone repair in the periradicular region. Four root canals in the mesial root of the mandibular first molar represent a rare configuration. The clinician must consider possible anatomical variations of the root canal system and carefully analyze the imaging exams along with clinical observation during treatment so that all canals are located and treated to achieve success. (Rev Port Estomatol Med Dent Cir Maxilofac. 2023;64(2):93-98)

© 2023 Sociedade Portuguesa de Estomatologia e Medicina Dentária.

Publicado por SPEDM. Este é um artigo Open Access sob uma licença CC BY-NC-ND (<http://creativecommons.org/licenses/by-nc-nd/4.0/>).

* Corresponding author.

Correio eletrónico: yu_oda@hotmail.com (Lisa Yurie Oda).

<http://doi.org/10.24873/j.rpemd.2023.07.1060>

1646-2890/© 2023 Sociedade Portuguesa de Estomatologia e Medicina Dentária. Published by SPEDM.

This is an open access article under the CC BY-NC-ND license (<http://creativecommons.org/licenses/by-nc-nd/4.0/>).

Tratamento endodôntico de um primeiro molar inferior com seis canais radiculares – relato de caso

R E S U M O

Palavras-chave:

Varição anatômica
Endodontia
Molar
Preparação do canal radicular
Tratamento do canal radicular

O primeiro molar inferior geralmente apresenta uma raiz mesial com dois canais radiculares e uma raiz distal com um ou dois canais radiculares. No entanto, podem ocorrer variações nessa morfologia, como a presença de múltiplos canais radiculares. Um paciente do sexo masculino, de 20 anos, apresentou-se com uma queixa principal de dor e edema na região mandibular esquerda. Com base em exames clínicos e radiográficos, foi estabelecido o diagnóstico de periodontite apical sintomática. Inicialmente, dois canais radiculares na raiz mesial e dois na raiz distal do dente #36 foram localizados e negociados sob um microscópio operatório. Após exploração adicional, mais dois canais radiculares foram localizados na raiz mesial. Os seis canais radiculares foram preparados e, para a irrigação final, as soluções irrigadoras foram agitadas utilizando um instrumento ultrassônico. Foi feito um curativo com pasta de hidróxido de cálcio e, um mês depois, o paciente apresentou-se sem sinais ou sintomas. A obturação do canal radicular foi realizada utilizando a técnica de cone único, com cones de guta-percha e cimento endodôntico biocerâmico. Passados 12 meses, foi feita uma radiografia periapical, que mostrou reparo ósseo na região perirradicular. A presença de quatro canais radiculares na raiz mesial do primeiro molar inferior é uma configuração rara. Possíveis variações anatômicas no sistema de canais radiculares devem ser consideradas pelo profissional, que deve analisar criteriosamente os exames de imagem, além da observação clínica durante o tratamento, para que todos os canais sejam localizados e tratados para alcançar o sucesso. (Rev Port Estomatol Med Dent Cir Maxilofac. 2023;64(2):93-98)

© 2023 Sociedade Portuguesa de Estomatologia e Medicina Dentária.

Published by SPEMD. This is an open access article under the CC BY-NC-ND license (<http://creativecommons.org/licenses/by-nc-nd/4.0/>).

Introduction

One of the main goals of the endodontic treatment is to shape and clean the entire root canal system; thus, knowledge of tooth morphology is a prerequisite for a successful outcome.¹ The mandibular molar usually has two well-defined roots: a mesial root with two root canals and a distal root with one or two root canals.^{2,3} However, variations in this morphology may occur, such as a third distolingual root, isthmuses, and multiple root canals.²

A variation in the mesial root of the mandibular first molar has been reported in the literature as a third root canal, commonly called the middle mesial canal, with its incidence ranging from 0.26% to 46.15%, depending on the studied population.⁴ Some studies report a rarer configuration of mandibular first molars: four root canals in the mesial root, and one,⁵ two,⁶⁻⁹ three,^{10,11} and four¹² root canals in the distal root.

To overcome the challenges associated with anatomical complexity, the clinician must be able to distinguish and identify the topographic location of any additional canal orifices, which can be best achieved using a dental operating microscope.^{6,13}

This report aims to present and describe the endodontic treatment of a mandibular first molar with six root canals — four in the mesial root and two in the distal root.

Case Report

A 20-year-old male patient presented at our private office with a chief complaint of pain and swelling in the left mandibular region. On clinical examination, the patient showed tenderness to percussion and palpation on tooth #36 and a negative response to the cold thermal pulp test. There was no mobility and no periodontal pocketing at probing. A preoperative radiograph (Figure 1) revealed that the root length of tooth #36 was shorter than its adjacent teeth, suggesting root resorption. It also showed a widening of the apical periodontal ligament and a radiolucency associated with the mesial and distal roots of the left mandibular first molar. Based on these findings, the diagnosis of symptomatic apical periodontitis was established. The patient reported previous orthodontic treatment, and the medical history was noncontributory. He signed an informed consent form, and the non-surgical endodontic treatment was immediately initiated to relieve his pain.

Local anesthesia was administered via inferior alveolar nerve block followed by buccal infiltration using 2% mepivacaine with 1:100,000 epinephrine (DFL, Rio de Janeiro, Brazil). The tooth was isolated with a rubber dam, and the access cavity was performed with a round diamond bur (1014, KG Sorensen, Cotia, Brazil) at high speed.

Initially, two root canals in the mesial root (Figure 2) and two in the distal root were located and negotiated with #10 and

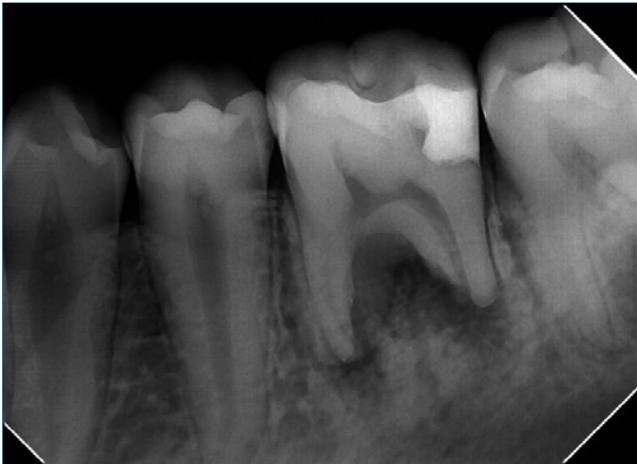

Figure 1. Initial radiograph of tooth 36.

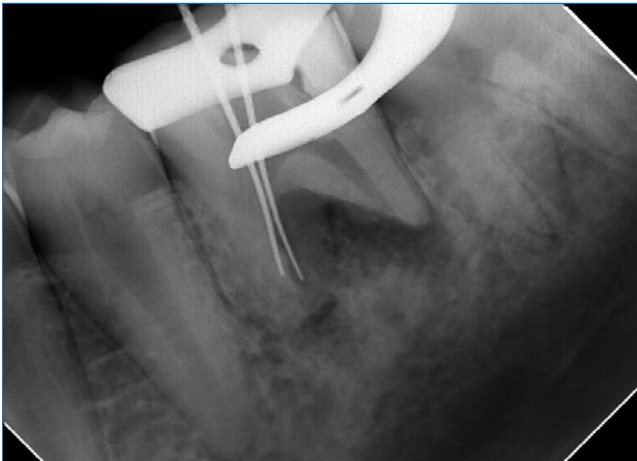


Figure 2. Radiograph showing two mesial canals located.

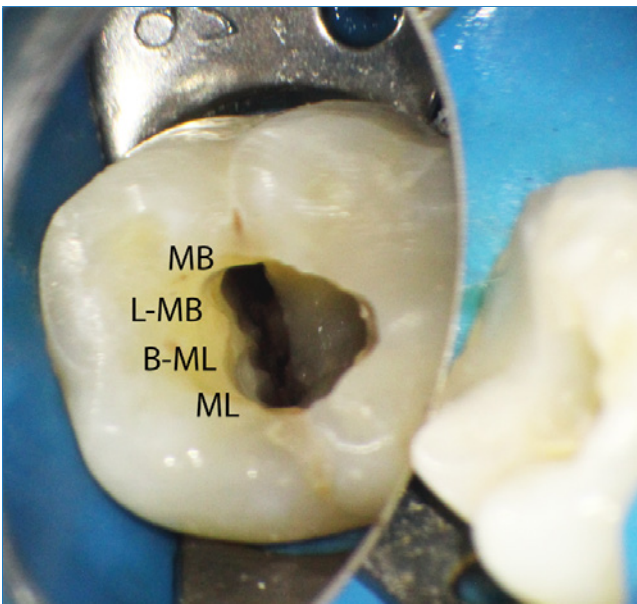


Figure 3. Mesial canals' orifices after instrumentation: mesiobuccal (MB), linguo-mesiobuccal (L-MB), bucco-mesiolingual (B-ML), and mesiolingual (ML).

#15 C-Pilot hand files (VDW Dental, Munich, Germany) under an operating microscope (16x, Alliance Microscopia, São Carlos, Brazil). Clinically, the mesial root presented great flattening in the buccolingual direction; this was also observed in the periapical radiograph with the files in the two located canals (Figure 2), suggesting the presence of more canals. After further exploration, two more root canals were located in the mesial root (Figure 3). The working length was determined with an electronic apex locator (Root Zx II, Morita, Kyoto, Japan). The four mesial root canals were prepared with #25.08 and #40.06 Reciproc Blue files (VDW Dental, Munich, Germany) according to the manufacturer's instructions. The distal canals were prepared with a #50.05 Reciproc Blue file (VDW Dental, Munich, Germany) and up to #60 hand files. After using each instrument, the root canals were irrigated with 3mL of 2.5% sodium hypochlorite (Danafarma, Curitiba, Brazil) with a 30-gauge irrigation needle (Navitip, Ultradent, South Jordan, USA).

For the final rinse, it was not used alcohol. To enhance smear layer removal, 3 mL of 17.0% EDTA (Danafarma, Curitiba, Brazil) were used and agitated three times for 20 seconds each, using an Irrisonic ultrasonic tip (Helse Dental Technology, São Paulo, Brazil); the irrigating solution was renewed between the cycles. This same protocol was then used for the sodium hypochlorite solution. The ultrasonic tip was 18.0-mm long with a #20 tip diameter, .01 taper, and a smooth surface and was used at a power of 10% in the ultrasonic unit. The canals were dried with #30 matched paper points (VDW Dental, Munich, Germany) and dressed with calcium hydroxide paste (UltraCal XS, Ultradent, South Jordan, USA) using the syringe provided by the manufacturer and a 29-gauge needle (Navitip, Ultradent, South Jordan, USA). The access cavity was closed with a glass-ionomer cement (Ionofast, Biodinâmica, Iporã, Brazil).

On the second visit, one month later, the patient had no signs or symptoms. After local anesthesia and rubber dam placement, the temporary restoration was removed, and passive ultrasonic irrigation was again performed using the same protocol as in the first appointment to remove the intracanal dressing. The canals were dried with paper points. Root canal filling was performed using the single-cone technique with gutta-percha cones (Odous de Deus, Belo Horizonte, Brazil)

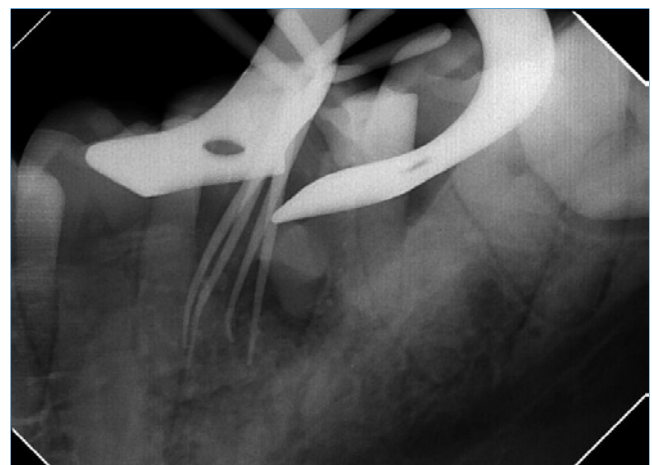


Figure 4. Four gutta-percha master cones in the four mesial canals.

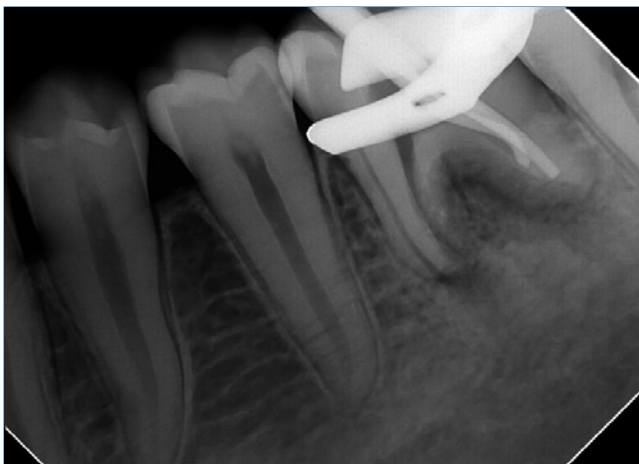

Figure 5. Two gutta-percha master cones in the two distal canals.

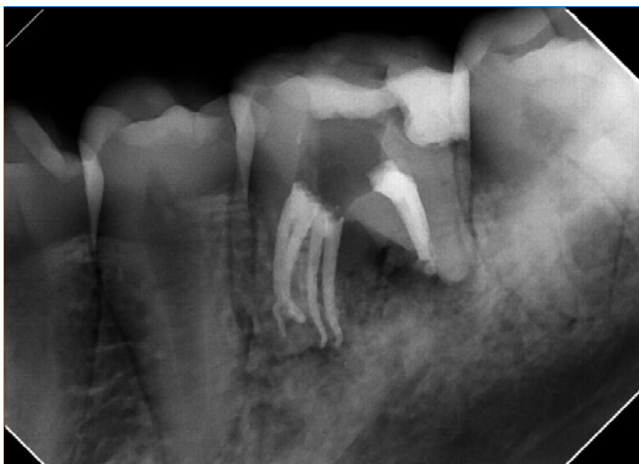

Figure 6. Final radiograph.

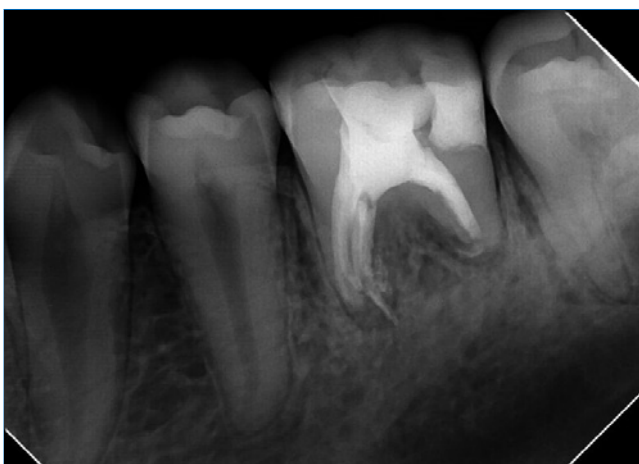

Figure 7. 12-month follow-up radiograph showing healing of periapical tissues.

(Figures 4 and 5), previously disinfected by immersion in sodium hypochlorite for five minutes, and BioRoot™ RCS sealer (Septodont, Saint-Maur-des-Fossés, France) (Figure 6). A tem-

porary restoration was made with a glass-ionomer cement (Ionofast, Biodinâmica, Ibioporã, Brazil) to close the access cavity. The patient was referred for tooth coronal rehabilitation, and after one week, the referring professional performed a definitive composite resin restoration. At the 12-month follow-up, a periapical radiograph showed bone repair in the periradicular region (Figure 7).

Discussion and conclusions

The mandibular first molar is among the first permanent teeth to erupt and often requires endodontic procedures.¹⁴ It usually has two roots and two to three root canals, and while the mesial root is flattened, the distal root is straight.² In this case report, the mandibular first molar had four root canals in the mesial root and two in the distal root. The mesial canals were named mesiobuccal (MB), linguo-mesiobuccal (L-MB), bucco-mesiolingual (B-ML), and mesiolingual (ML) to consider the anatomical relation of roots and their root canals.^{8,15}

The presence of a fourth canal in the mesial root of the mandibular molar represents a rarer morphology.⁵ In these cases of four root canals in the mesial root, the total number of root canals may vary up to eight depending on the distal root. In mandibular first molars, one report found one canal in the distal root,⁵ four found two canals in the distal root⁶⁻⁹ (the same morphology as the present case), two found three canals in the distal root,^{10,11} and one found four canals in the distal root.¹²

The frequency of untreated canals is high in mandibular molars, second only to maxillary molars.¹⁶ Untreated canals are related to a higher probability of developing apical periodontitis^{16,17} and treatment failure.¹ Before starting any treatment, it is important to consider morphological variations and carefully examine the tooth clinically and radiographically.⁶

Although cone-beam computer tomography provides undistorted 3D images of the root canal anatomy,¹⁰ periapical radiographs were the only aid used in most reported cases found with four canals in the mesial root.^{6,7,9,11,12,18} In the present case, only periapical radiographs at different horizontal angles were taken, which provides information that gets even more accurate when combined with clinical findings.¹

One of the etiological factors for root resorptions with reduced root length is the force applied during orthodontic treatment.¹⁹ In the present case, it could explain the shorter root length of the tooth compared to the adjacent ones, as the patient had undergone orthodontic treatment previously.

Magnification may enhance the detection of root canal orifices. Three reports used loupes,^{7,12,18} and three used operating microscopes.^{6,8,9} The present case used an operating microscope, which helps locate and negotiate canals with great precision^{1,20} and has shown to be significantly better than the naked eye or surgical loupes.²⁰

In mandibular molars, additional canals are usually hidden by a dentinal projection lighter than the color of the pulp chamber floor.¹² Ultrasonic tips can be used to remove this dentin; these are safe tools that enhance visual access and allow better control to work in the pulp chamber.²¹ The present

case did not use them because there was no dentinal projection. Another application of ultrasonic tips is to increase the action of irrigating solutions, as they act in the mechanical flushing and chemical ability of solutions to dissolve tissues.²¹ In the present case, the irrigating solutions were activated with an ultrasonic tip after the negotiation of the root canals to enhance the smear layer removal.

The present case used calcium-hydroxide paste as an intracanal dressing. Its use between sessions enhances the disinfection of the root canal system,²² mainly in more complex canal systems,²³ as it has wide-spectrum antibacterial activity²⁴ and reduces bacterial lipopolysaccharide from infected root canals.²⁵

After shaping and cleaning the root canal system, it is necessary to seal it properly. Bioceramic endodontic sealers have been widely used mainly due to their bioactive property of inducing proliferation and binding of cells close to cement and their potential to induce angiogenesis and osteogenesis, which are prerequisites for periapical tissue regeneration.²⁶ In this case, a bioceramic endodontic sealer was used to fill the root canals, associating the single-cone technique with greater tapered gutta-percha cones to make the obturation a faster and simpler procedure, minimize the forces applied to the root canal walls by the spreaders, and not decrease the quality of the apical sealing.^{27,28}

After one year, the patient presented no symptoms, and bone repair was observed radiographically. A longer follow-up time would be better to evaluate success, but the main objective of this case report was to present this rare anatomical variation.

The complexity of the root canal system is a challenge in endodontic treatment. Knowing the root morphology and its possible variations is essential to achieve a successful outcome in endodontic treatments. The presence of a fourth canal in the mesial root of the mandibular molar represents a complex anatomy that, when not considered, may lead to treatment failure. Aids such as an operating microscope, ultrasonically activated irrigation, and bioceramic endodontic sealers may contribute to endodontic management, as they enhance the visualization and negotiation of the root canals, improve the disinfection of the root canal system, and favor the bone repair, respectively.

Conflict of interest

The authors have no conflicts of interest to declare.

Ethical disclosures

Protection of human and animal subjects. The authors declare that the procedures followed were in accordance with the regulations of the relevant clinical research ethics committee and with those of the Code of Ethics of the World Medical Association (Declaration of Helsinki).




Confidentiality of data. The authors declare that they have followed their work center protocols on access to patient data and for its publication.

Right to privacy and informed consent. The authors have obtained the written informed consent of the patients or subjects mentioned in the article. The corresponding author is in possession of this document.

CREDIT AUTHORSHIP CONTRIBUTION STATEMENT

André Luiz da Costa Michelotto: Conceptualization, Data curation, Formal analysis, Funding acquisition, Investigation, Methodology, Project administration, Resources, Validation, Visualization, Writing – review & editing. **Lisa Yurie Oda:** Data curation, Formal analysis, Investigation, Methodology, Writing – original draft, Writing - review & editing. **Antonio Batista:** Conceptualization, Project administration, Resources, Supervision, Validation, Visualization, Writing – review & editing.

ORCID

André Luiz da Costa Michelotto  0000-0001-7855-4407
 Lisa Yurie Oda  0000-0001-5203-5422
 Antonio Batista  0000-0002-6571-6662

REFERENCES

- Vertucci FJ. Root canal morphology and its relationship to endodontic procedures. *Endodontic topics*. 2005;10:3-29.
- Pablo OV, Estevez R, Péix Sánchez M, Heilborn C, Cohenca N. Root anatomy and canal configuration of the permanent mandibular first molar: a systematic review. *J Endod*. 2010;36:1919-31.
- Silva EL, Pradob MC, Duarte MH. Prevalence of root canal system configurations in the Brazilian population analyzed by cone-beam computed tomography—a systematic review. *Rev Port Estomatol Med Dent Cir Maxilofac*. 2021;62:1-13.
- Versiani MA, Ordinola-Zapata R, Keleş A, Alcın H, Bramante CM, Pécora JD, et al. Middle mesial canals in mandibular first molars: A micro-CT study in different populations. *Arch Oral Biol*. 2016;61:130-7.
- Subbiya A, Kumar KS, Vivekanandhan P, Prakash V. Management of mandibular first molar with four canals in mesial root. *J Conserv Dent*. 2013;16:471-3.
- Kontakiotis EG, Tzanetakis GN. Four canals in the mesial root of a mandibular first molar. A case report under the operating microscope. *Aust Endod J*. 2007;33:84-8.
- Aminsobhani M, Shokouhinejad N, Ghabraei S, Bolhari B, Ghorbanzadeh A. Retreatment of a 6-canalled mandibular first molar with four mesial canals: a case report. *Iran Endod J*. 2010;5:138-40.
- Jain D, Reddy S, Venigalla BS, Kamishetty S. Endodontic management of a mandibular first molar with six root canal systems. *J Conserv Dent*. 2015;18:419-22.
- Martins JN, Anderson C. Endodontic treatment of the mandibular first molar with six roots canals - two case reports and literature review. *J Clin Diagn Res*. 2015;9:ZD06-8.
- Vineet A, Sonali K, Dhvani B. Rare case of a mandibular first molar with seven canals confirmed by cone beam computed tomography and its endodontic management. *Int J Health Sci (Qassim)*. 2018;12:91-3.

11. Reeh ES. Seven canals in a lower first molar. *J Endod.* 1998;24:497-9.
12. Arora A, Acharya SR, Sharma P. Endodontic treatment of a mandibular first molar with 8 canals: a case report. *Restor Dent Endod.* 2015;40:75-8.
13. Michelotto ALC, Oda LY, Yamamoto ATA, Cavenago BC, Batista A. Endodontic retreatment of mandibular canines with two roots: A report of two cases. *Rev Port Estomatol Med Dent Cir Maxilofac.* 2022;63:92-8.
14. Vertucci FJ, Haddix JE. Tooth morphology and access cavity preparation. *Cohen's Pathways of the Pulp*: Elsevier; 2011. p. 136-222.
15. Albuquerque DV, Kottoor J, Velmurugan N. A new anatomically based nomenclature for the roots and root canals-part 2: mandibular molars. *Int J Dent.* 2012;2012:814789.
16. Costa FFNP, Pacheco-Yanes J, Siqueira JF, Oliveira ACS, Gazzaneo I, Amorim CA, et al. Association between missed canals and apical periodontitis. *Int Endod J.* 2019;52:400-6.
17. Piresa MD, Martinsa JN. Endodontic treatment of the mandibular first molar with three distal root canals – Case series. *Rev Port Estomatol Med Dent Cir Maxilofac.* 2019;60:137-44.
18. Kottoor J, Paul KK, Mathew J, George S, Roy A. A permanent mandibular second molar with seven root canal systems. *Quintessence Int.* 2014;45:381-3.
19. Vázquez EC, Abelleira AC, Quintanilla JMS, Cobos MAR. Correlation between occlusal contact and root resorption in teeth with periodontal disease. *J Periodontal Res.* 2011;46:82-8.
20. Karapinar-Kazandag M, Basrani BR, Friedman S. The operating microscope enhances detection and negotiation of accessory mesial canals in mandibular molars. *J Endod.* 2010;36:1289-94.
21. Plotino G, Pameijer CH, Grande NM, Somma F. Ultrasonics in endodontics: a review of the literature. *J Endod.* 2007;33:81-95.
22. Siqueira Junior JF, Rôças IDN, Marceliano-Alves MF, Pérez AR, Ricucci D. Unprepared root canal surface areas: causes, clinical implications, and therapeutic strategies. *Braz Oral Res.* 2018;32(suppl 1):e65.
23. Gazzaneo I, Amoroso-Silva P, Pacheco-Yanes J, Alves FRF, Marceliano-Alves M, Olivares P, et al. Disinfecting and Shaping Type I C-shaped Root Canals: A Correlative Micro-computed Tomographic and Molecular Microbiology Study. *J Endod.* 2021;47:621-30.
24. Best S, Ammons CL, Karunanayake GA, Saemundsson SR, Tawil PZ. Outcome Assessment of Teeth with Necrotic Pulp and Apical Periodontitis Treated with Long-term Calcium Hydroxide. *J Endod.* 2021;47:11-8.
25. Adl A, Motamedifar M, Shams MS, Mirzaie A. Clinical investigation of the effect of calcium hydroxide intracanal dressing on bacterial lipopolysaccharide reduction from infected root canals. *Aust Endod J.* 2015;41:12-6.
26. Camps J, Jeanneau C, El Ayachi I, Laurent P, About I. Bioactivity of a Calcium Silicate-based Endodontic Cement (BioRoot RCS): Interactions with Human Periodontal Ligament Cells In Vitro. *J Endod.* 2015;41:1469-73.
27. Chybowski EA, Glickman GN, Patel Y, Fleury A, Solomon E, He J. Clinical Outcome of Non-Surgical Root Canal Treatment Using a Single-cone Technique with Endosequence Bioceramic Sealer: A Retrospective Analysis. *J Endod.* 2018;44:941-5.
28. Hörsted-Bindslev P, Andersen MA, Jensen MF, Nilsson JH, Wenzel A. Quality of molar root canal fillings performed with the lateral compaction and the single-cone technique. *J Endod.* 2007;33:468-71.