

## Case Report

# 14-Year evolution odontogenic keratocyst: Case report



**Cintia Mussi Milani\***, **Camyla Moussa Mauricio**, **Luciano Francio**,  
**Natanael Henrique Ribeiro Mattos**

Faculty of Dentistry, Universidade Tuiuti do Paraná, Curitiba, Brazil

### ARTICLE INFO

#### Article history:

Received 28 June 2020

Accepted 20 February 2021

Available online 17 March 2021

#### Keywords:

Bone cyst

Oral pathology

Oral radiology

Oral surgery

### ABSTRACT

Odontogenic keratocyst is a developmental odontogenic cyst that is usually diagnosed in routine radiographs in the early stages. This fact increases the dentist's responsibility for its diagnosis, and the professional should pay attention to all maxillomandibular complex and not only to the teeth. There is no standard protocol for the treatment of odontogenic keratocyst. However, surgical resection is recommended because of its high recurrence rate, especially in those cases with extensive bone destruction. The enucleation followed by Carnoy's solution application has been shown to be a good alternative to resection and pointed out as the conservative method associated with the lowest recurrence rates in the treatment of odontogenic keratocyst. This study aimed to report a case of an extensive odontogenic keratocyst with more than 14 years of evolution that had not been diagnosed in three previous different panoramic radiographs and was treated with enucleation and application of Carnoy's solution. (Rev Port Estomatol Med Dent Cir Maxilofac. 2021;62(1):50-55)

© 2021 Sociedade Portuguesa de Estomatologia e Medicina Dentária.

Publicado por SPEMD. Este é um artigo Open Access sob uma licença CC BY-NC-ND

(<http://creativecommons.org/licenses/by-nc-nd/4.0/>).

\* Corresponding author.

E-mail address: [cintiammilani@hotmail.com](mailto:cintiammilani@hotmail.com) (Cintia Mussi Milani).

<http://doi.org/10.24873/j.rpemd.2021.03.824>

1646-2890/© 2021 Sociedade Portuguesa de Estomatologia e Medicina Dentária. Published by SPEMD.

This is an open access article under the CC BY-NC-ND license (<http://creativecommons.org/licenses/by-nc-nd/4.0/>).

## Queratocisto odontogénico com 14 anos de evolução: caso clínico

### R E S U M O

#### Palavras-chave:

Cisto ósseo  
Patologia oral  
Radiologia oral  
Cirurgia oral

O queratocisto odontogénico é um quisto odontogénico de desenvolvimento que, nos estágios iniciais, usualmente é detetado em radiografias de rotina. Este facto aumenta a responsabilidade do médico dentista no seu diagnóstico pelo que o profissional deve prestar atenção a todo o complexo maxilomandibular e não apenas nos dentes. Não há um protocolo de tratamento para o queratocisto odontogénico. No entanto, devido ao seu alto índice de recorrência, a ressecção cirúrgica é recomendada, especialmente naqueles casos com destruição óssea extensiva. A enucleação seguida da aplicação da Solução de Carnoy é uma boa alternativa à ressecção, sendo apontada como o tratamento conservador de queratocisto odontogénico com menor taxa de recorrência. O objetivo deste estudo foi relatar um caso de queratocisto odontogénico de grande extensão, com mais de 14 anos de evolução, não diagnosticado em 3 diferentes radiografias panorâmicas, que foi tratado com enucleação seguida da aplicação da solução de Carnoy. (Rev Port Estomatol Med Dent Cir Maxilofac. 2021;62(1):50-55)

© 2021 Sociedade Portuguesa de Estomatologia e Medicina Dentária.

Published by SPEMD. This is an open access article under the CC BY-NC-ND license (<http://creativecommons.org/licenses/by-nc-nd/4.0/>).

### Introduction

The odontogenic keratocyst (OK) is a developmental odontogenic cyst whose nomenclature has been changing in recent decades. The 2005 World Health Organization (WHO) classification of Head and Neck Tumors reclassified the odontogenic keratocyst as a benign neoplasm, recommending the term “keratocystic odontogenic tumor” due to its aggressiveness, high recurrence rate, and association with the nevoid basal cell carcinoma syndrome and mutations in the PTCH1 gene. However, in 2017, the WHO reclassified it as a cyst, alleging that mutations in the PTCH gene can occur even in non-neoplastic lesions, such as the dentigerous cyst;<sup>1</sup> besides, many researchers have suggested that cyst resolution after marsupialization is not compatible with a neoplastic process.<sup>1-5</sup>

OKs derive from the dental lamina and have a predilection for males, occurring mainly in the third decade of life.<sup>6-9</sup> The mandible is more affected than the maxilla, and the sites of predilection are its posterior body, angle, and ascending ramus.<sup>6,9</sup> The lesion is asymptomatic and is often diagnosed on routine radiographs. Thus, the general dentist's attention while evaluating the maxillomandibular complex is essential and should not be limited to analyzing the teeth.<sup>10</sup> OKs extend initially in the anteroposterior direction, causing expansion in a late stage.<sup>7,8</sup> In advanced stages, pain, edema, tooth displacement, root resorption, and pathologic fractures can be observed.<sup>8,9</sup>

Radiographically, the OK presents as a uni- or multilocular lesion, with often scalloped margins, commonly associated with impacted third molars.<sup>7,11</sup> Its differential diagnosis should include dentigerous cyst, ameloblastoma, radicular cyst, lateral periodontal cyst, and nevoid basal cell carcinoma syndrome.<sup>9</sup> Histologically, OKs usually present a very thin and uniform lining epithelium and a well-defined basal cell layer in a palisaded arrangement. The keratin layer is corrugated, and the cystic wall is thin and generally uninfamed; cell proliferation

markers such as Ki-7 and P53 can be observed.<sup>7,9,11</sup> The presence of satellite cysts potentially increases the chance of recurrence if they are not completely removed during surgery.<sup>8</sup>

Various treatment modalities have been reported, including marsupialization, enucleation with or without adjuvants, decompression, cryotherapy, and resection.<sup>6,8,9,11-13</sup> The goal is to choose the treatment modality that carries the lowest possible risk of recurrence and the least morbidity while still eradicating the lesion. The lesion recurrence rates vary according to the chosen treatment modality, with the lowest index associated with surgical resection. Due to its high morbidity, more conservative techniques are constantly used. Among them, enucleation associated with Carnoy's solution has the lowest recurrence rate, being a good alternative to resection.<sup>8,13</sup>

The present study aimed to report a case of a large keratocyst with more than 14 years of evolution in a 67-year-old male patient that had not been diagnosed in three previous different panoramic radiographs and was treated with enucleation followed by the application of Carnoy's solution.

### Case report

A 67-year-old male patient was referred to our clinic to evaluate a mass on his face that had been gradually enlarging for the last five months. Past family and medical history were unremarkable. The patient reported discomfort at his mandible's left posterior body for more than ten years. In the past, he had his impacted lower third molar removed after being told the discomfort was due to the tooth. However, the symptom persisted after the surgery, and he also started feeling a bad taste and sometimes could see a white/yellow liquid discharging from the area of the third molar. These symptoms persisted for a long time after the surgery, and he could not remember for how long exactly.

General physical examination showed an asymptomatic firm mass on the left preauricular area, covered with normal skin (Figure 1). The intraoral examination did not reveal any abnormality.

The patient presented his 2003, 2004, and 2013 panoramic radiographs, requested by different professionals, revealing the evolution of a large radiolucent lesion in the left posterior ascending ramus (Figures 2, 3, and 4). The patient stated that

the lesion was never mentioned and, on two occasions, had received an antibiotic prescription alleging his discomfort was due to the third molar removal.

A panoramic radiograph and cone-beam tomography were requested and revealed an extensive radiolucent lesion extending from the retromolar area to the mandibular incisure, causing an expansion of the anterior border of the ramus and perforation of the cortical bone (Figures 5 and 6). A routine

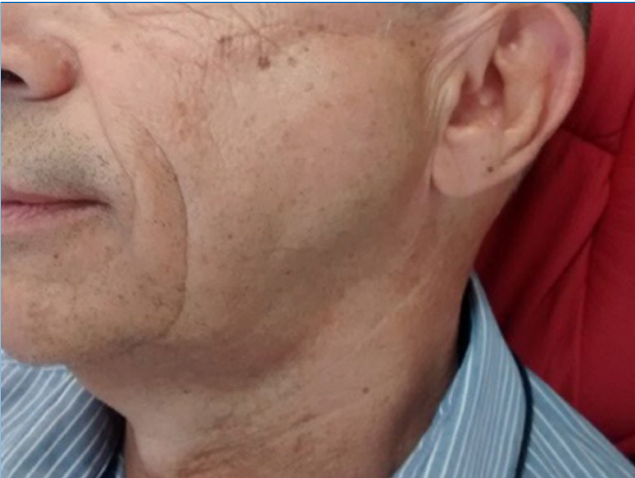

Figure 1. Initial extraoral aspect showing a nodular mass in the left preauricular area.

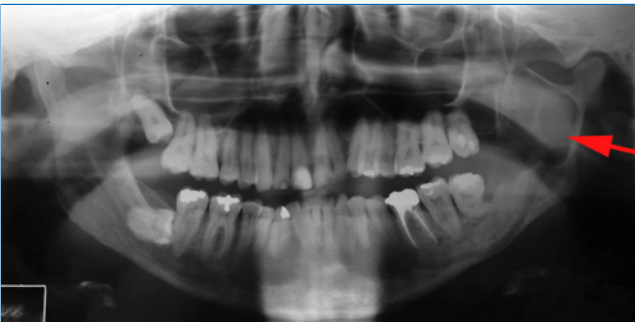

Figure 2. Panoramic radiography performed in 2003, showing an extensive radiolucent lesion in the left mandibular ramus (red arrow).

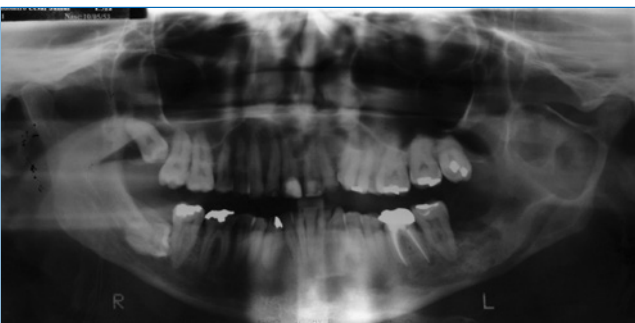

Figure 3. Panoramic radiography performed in 2004 after removal of the lower third molar, showing the lesion's persistence.

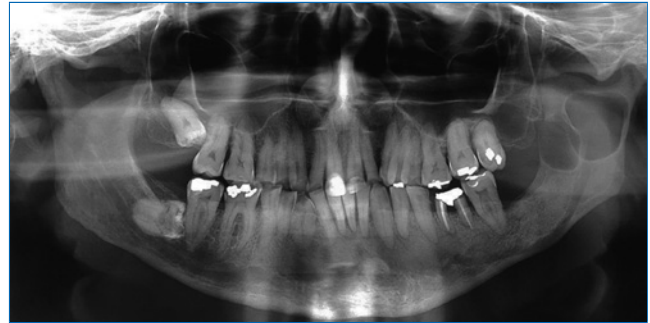


Figure 4. Panoramic radiography performed in 2013, showing new bone formation in the 38 region and persistent lesion in the ramus.

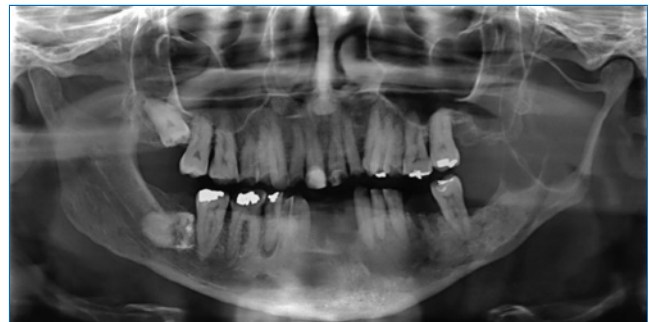


Figure 5. Panoramic radiography performed after the initial consultation (2017), showing an increase in the lesion, with the expansion of the anterior border of the ramus.

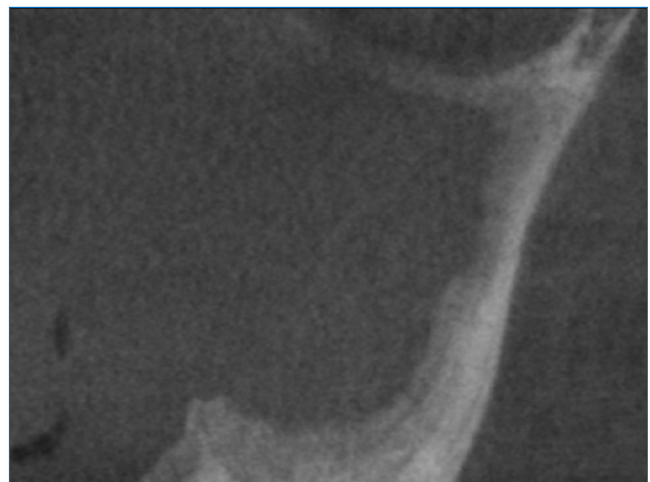

Figure 6. Cone-beam tomography showing an extensive hypodense image extending from the retromolar region to the mandibular notch.

blood examination showed nothing abnormal. Based on clinical and radiologic aspects, the initial diagnosis was keratocyst or ameloblastoma, and surgical treatment was indicated after establishing the final diagnosis.

An incisional biopsy was performed under local anesthesia. After the mucoperiosteal flap was raised, a discharge of a whitish pasty material, suggestive of keratin, was observed. The anatomopathological examination confirmed the initial diagnosis of keratocyst (Figure 7).

The patient was informed about all treatment modalities and the recurrence rates associated with each one. Although partial resection with the placement of a customized prosthesis was recommended, he opted for a more conservative treatment, with enucleation followed by the application of Carnoy's solution.

An incision was made, under general anesthesia, on the anterior border of the ramus, extending to the second premolar area. The mucoperiosteal flap was raised, followed by complete enucleation of the lesion. Then, the bone cavity was coated with gauze, and the Carnoy's solution was applied for 3 minutes, followed by saline irrigation; this procedure was repeated three times. The wound was closed with absorbable suture, and the healing was uneventful. The patient was discharged from the hospital 24 hours later, with no pain complaints but mentioning lower lip cushioning.

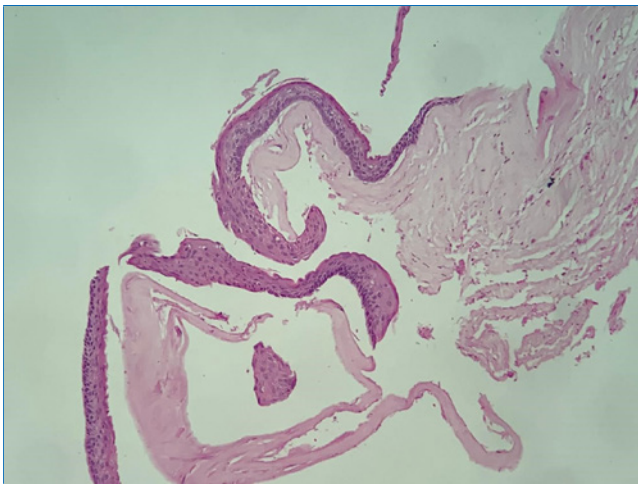


Figure 7. Thin cystic lesion lining epithelium with a hyperchromatic basal layer in palisade and corrugated parakeratin layer.

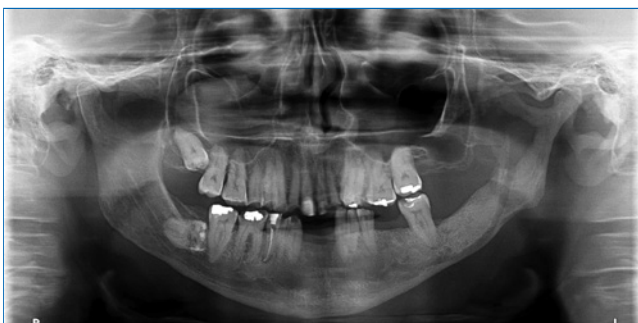

Figure 8. 6-month panoramic radiograph follow-up showing bone neoformation.

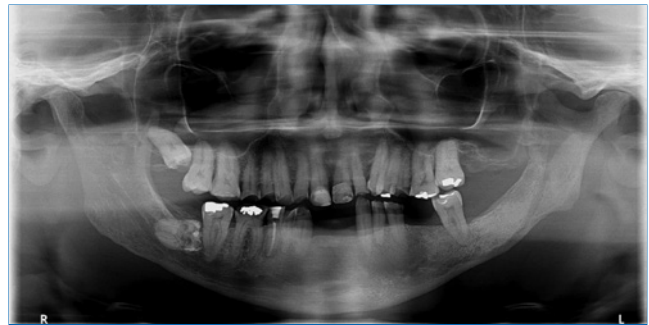

Figure 9. 18-month panoramic radiograph follow-up showing significant bone neoformation with no signs of recurrence.

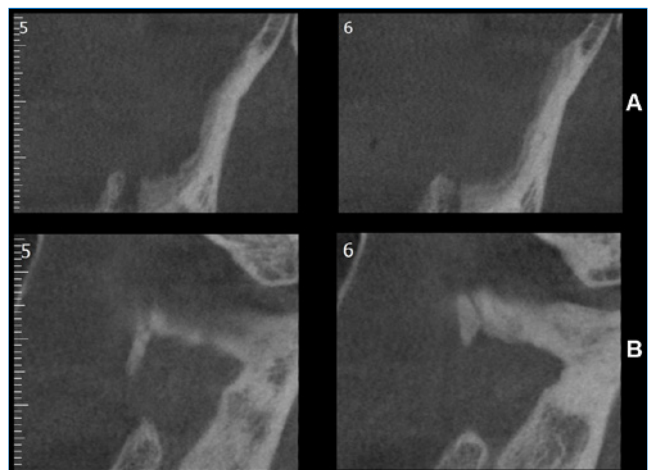


Figure 10. A: sagittal section of the initial tomography showing extensive bone destruction; B: sagittal section of the same area, 18 months later, showing almost complete bone neoformation and no signs of recurrence.

In a seven-day postoperative examination, he had good local healing and reported improvement of the cushioning. Complete resolution of paresthesia occurred around 40 days after surgery.

The patient remains in semiannual radiographic control (Figures 8 and 9) and 18-month cone-beam tomography control. He shows significant bone neoformation compared to the initial tomography, with no signs of recurrence (Figure 10).

## Discussion and conclusions

Early diagnosis of OK is the best way to avoid extensive bone destruction and more aggressive surgery. Unfortunately, in this case, despite the large radiolucent area in the mandibular ramus, three different professionals missed it. This overlook calls attention to the fact that some dentists look for alterations only in the teeth without analyzing all the anatomic structures in a panoramic radiograph.

Many accepted methods are used in the treatment of OKs, and the greatest challenge is to completely remove the cystic capsule, which is thin and friable. More conservative modalities include marsupialization, enucleation with or without

adjuvants, such as ostectomy or Carnoy's solution, and decompression followed by enucleation. Marsupialization and decompression are increasingly popular treatment options for OKs to preserve adjacent structures until sufficient ossification occurs.<sup>3</sup> However, although these treatment modalities may decrease the cyst's size, they do not definitively treat the OK, and additional surgical intervention is generally required for its removal.<sup>14</sup> Besides, they require regular follow-up visits, irrigation of the cyst cavity, and repeated adjustment of the stent.<sup>3</sup>

The most extensive OK treatment is osseous resection, which has the lowest recurrence rate. However, it causes considerable morbidity, particularly because reconstructive measures are necessary to restore jaw function and esthetics.<sup>6,8,11,14</sup> In the present case, the patient rejected resection because he preferred to have a slightly higher risk of recurrence than undergo such an aggressive and mutilating treatment for a benign lesion.

Carnoy's solution, the adjuvant of choice in the present case, is composed of ethanol, chloroform, glacial acetic acid, and ferric chloride.<sup>6</sup> Enucleation associated with Carnoy's solution showed good results in a previous study by Leung et al.,<sup>13</sup> where its recurrence rate was 11.4%, with minimal morbidity. A similar rate, 11.5%, was found by Al-Moraissi et al.,<sup>15</sup> who considered this method the primary treatment for OKs. Dashow et al.,<sup>16</sup> however, obtained a significantly lower recurrence rate, 4.8%, pointing it as the lowest recurrence among conservative treatments. Chrcanovic and Gomez<sup>11</sup> obtained a similar result, 5.3%, and considered it the lowest recurrence among the treatment modalities. Ribeiro-Júnior et al.<sup>2</sup> concluded that Carnoy's solution and peripheral ostectomy had similar efficacy in OK management. On the other hand, Karaca et al.<sup>6</sup> compared the two modalities and concluded that peripheral ostectomy had a statistically higher recurrence than Carnoy's solution, around 18.2% versus only 5.3%, respectively. In the present case, peripheral ostectomy was not considered a treatment option in order not to fragilize the mandible even more.

Carnoy's solution is a chemical cauterization agent that was first used as a fixative agent in histology but has been used in the treatment of injuries due to its power to penetrate tissues, local fixation, and ability to promote hemostasis.<sup>14</sup> It causes superficial tissue necrosis, from a chemical cauterization up to 1.5-mm deep after 5 minutes of application in bone stores, and eliminates tumor cells.<sup>13,17</sup> Its application method consists of protecting neighboring tissues with sterile gauze, coating the bone cavity with gauze, and applying the solution for 3 minutes, followed by irrigation with a saline solution. This procedure, repeated three times, was the same performed in our clinical case.<sup>13</sup> Some authors believe that the use of Carnoy's solution after enucleation in areas of bone fenestration may help eliminate residual microcysts on the overlying soft tissue, and its effects may be superior compared to using curettage or peripheral ostectomy as the adjunctive procedure.<sup>9</sup>

In 1992, the United States Food and Drug Administration (FDA) prohibited the use of chloroform in the composition of Carnoy due to being a carcinogen, and the modified Carnoy solution was then created.<sup>14,16,17</sup> The 3 ml of chloroform were replaced by 3 ml of absolute alcohol. However, studies' results support the relevance of maintaining chloroform in the solu-

tion due to the lower rates of recurrence and better performance of the solution compared to the solution modified by removing chloroform.<sup>13,17</sup> A recent study<sup>16</sup> of 80 patients, where 44 were treated with Carnoy and 36 with modified Carnoy, concluded that recurrence was greater in patients treated with the modified solution, around 35% versus 10% with the original solution. This finding indicates that the original solution may still have a role in OK treatment as an adjunctive to enucleation, reducing recurrence.<sup>13</sup> A survey with 809 dental surgeons in the United States revealed that 56% use the solution with chloroform and 42% without it; 27% reported having ceased to use it due to its unavailability in the market.<sup>14</sup>

Despite the good results presented in numerous researches with Carnoy's solution, one study showed disadvantages of its use: as it is a caustic solution, it can cause toxicity to the adjacent soft tissues, skin, and dental follicles if the patient is a child. Moreover, the authors pointed out the impossibility of immediate bone grafting.<sup>7</sup>

Long follow-up periods are suggested for this lesion because recurrence can occur up to 10 years after the initial treatment.<sup>7</sup> It is recommended to reassess the patient every 6 months, as has been done in the present case. An early diagnosis of recurrence can be treated with conservative approaches.<sup>12</sup>

As OK is an asymptomatic lesion in its early stages, it is essential that the general dentist pays attention during radiographic evaluations, carefully observing all the bone structures and not just the teeth. Early diagnosis is important so that more conservative surgical treatments can be performed. In the present case, despite the advanced stage of bone destruction, enucleation associated with Carnoy's solution has proved to be quite effective so far. Long-term radiographic follow-up is mandatory to establish how successful this treatment really was.

---

## Ethical disclosures

**Protection of human and animal subjects.** The authors declare that no experiments were performed on humans or animals for this study.

**Confidentiality of data.** The authors declare that they have followed their work center protocols on access to patient data and for its publication.

**Right to privacy and informed consent.** The authors have obtained the written informed consent of the patients or subjects mentioned in the article. The corresponding author is in possession of this document.

---

## Conflict of interest

The authors have no conflicts of interest to declare.

---

## REFERENCES

1. Tekkesin MS, Wright JM. The World Health Organization Classification of Odontogenic Lesions: A Summary of the Changes of the 2017. *Turk Patoloji Derg.* 2018;34:1-18.

2. Ribeiro-Junior O, Borba AM, Alves CAF, Gouveia MM, Deboni MCZ, Naclério-Homem MG. Reclassification and treatment of odontogenic keratocysts: a cohort study. *Braz Oral Res.* 2017;18:e98-107.
3. Wakolbinger R, Beck-Mannagetta J. Long-term results after treatment of extensive odontogenic cysts of the jaws: a review. *Clin Oral Investig.* 2017;20:15-22.
4. Pogrel MA, Jordan RCK. Marsupialization as a Definitive Treatment for the Odontogenic Keratocyst. *J Oral Maxillofac Surg.* 2004;62:651-5.
5. Martin LHC, Speight PM. Odontogenic Cysts: an update. *Diag Histopathol.* 2017;23:260-6.
6. Karaca Ç, Dere KA, Er N, Aktas A, Tosun E, Taha-Koseoglu O, et al. Recurrence rate of odontogenic keratocyst treated by enucleation an peripheral ostectomy: Retrospective case series with up to 12 years of follow-up. *Med Oral Patol Oral Cir Bucal.* 2018;23:e443-8.
7. Castro MS, Caixeta CA, Carli ML, Junior NVR. Conservative surgical treatments for nonsyndromic odontogenic keratocysts: a systematic review and meta-analysis. *Clin Oral Investig.* 2018;22:2089-102.
8. Gupta A, Bansal P, Sharma R, Sharma SD. Treatment of Keratocystic Odontogenic Tumours: A prospective study of 30 cases. *J Oral Maxillofac Surg.* 2016;15:521-7.
9. Díaz-Belenguer A, Sánchez-Torres A, Gay-Escoda C. Role Of carnoy's solution in the treatment of keratocystic odontogenic tumor: A systematic review. *Med Oral Patol Oral Cir Bucal.* 2016;21:e689-95.
10. Baykul T, Yılmaz HH, Aydın U, Aydın MA, Aksoy MÇ, Yildirim D. Early Diagnosis of Oral Cancer. *J Int Med Res.* 2010;38:737-49.
11. Chrcanovic BR, Gomez RS. Recurrence probability for keratocystic odontogenic tumors: An analysis of 6427 cases. *J Craniomaxillofac Surg.* 2017;45:244-51.
12. Cakarar S, Isler SC, Keskin B, Uzun A, Berberoglu HK, Keskin C. Treatment For The Large Aggressive Benign Lesions of The Jaws. *J Maxillofac Oral Surg.* 2018;17:372-8.
13. Leung YY, Lau SL, Tsoi KYY, Ma HL, Ng CL. Results of The treatment ok Keratocystic odontogenic tumours using enucleation and treatment of the residual bony defect with Carnoy's solution. *Int J Oral Maxillofac Surg.* 2016;45:1154-8.
14. Ecker J, Horst RT, Kaslovsky D. Current role of carnoy's solution in treating keratocystic odontogenic tumors. *J Oral Maxillofac Surg.* 2016;74:278-82.
15. Al-Moraissi EA, Dahan AA, Alwadeai MS, Oginni FO, Al-Jamali JM, Alkhutari AS, et al. What surgical treatment has the lowest recurrence rate following the management of keratocystic odontogenic tumor? A large systematic review and meta-analysis. *J Craniomaxillofac Surg.* 2017;45:131-44.
16. Dashow JE, McHugh JB, Braun TM, Edwrads SP, Helman JI, Ward BB. Significantly Decreased Recurrence Rates in Keratocystic Odontogenic Tumor With Simple Enucleation and Curettage Using Carnoy's Versus Modified Carnoy's Solution. *J Oral Maxillofac Surg.* 2015;73:2132-25.
17. Carvalho FSR, Feitosa VP, Silva PGB, Soares ECS, Ribeiro TR, Fonteles CSR, et al. Evaluation of different therapeutic Carnoy's formulations on hard human tissues: A Raman microspectroscopy, microhardness, and scanning electron microscopy study. *J Craniomaxillofac Surg.* 2018;46:749-58.